

# Use of Milk and Molasses Enema in Colonic Obstruction in An Octogenarian

© Luis E. Martínez-Bravo, © Juan de Dios Garza-Rivera, © Jose R. Benitez-Mexia, © Julio C. Davila-Valero

Department of Geriatrics, Instituto Mexicano del Seguro Social, Hospital General de Zona, Guadalupe, Mexico

## Abstract

Safety and efficacy of milk and molasses enemas are described in the pediatric population, but evidence is lacking in older adults. We present the case of an octogenarian patient with acute abdominal pain as a result of colonic obstruction. After initial medical treatment failed and surgical treatment declined, milk and molasses enema were recommended to relieve symptoms. We present a case in which milk and molasses enema could play an important role in older adults who are unable to undergo surgery due to patient preferences or high comorbidity.

**Keywords:** Abdominal pain, case report, colonic obstruction, frail elderly, milk and molasses enema, octogenarian

## Introduction

Intestinal obstruction is a common condition in older adults, regardless of gender. It represents approximately 1-3% of all hospitalizations, of which 10-15% are located in the large intestine, with the sigmoid colon being the most frequent site. The main etiologies are cancer, adhesions, diverticular disease and volvulus (1,2). Initial medical treatment includes intravenous fluids, electrolyte replacement and gastric decompression, with a success rate of 77-96%; in case of failure, decompression by endoscopy or surgery is recommended (3). Regarding the latter, studies show mortality and postoperative complications of 29.8% and 47.9%, respectively (4).

This case report aims to draw attention to the use of milk and molasses enemas as an alternative therapy to surgical management in older adults whose diagnosis is intestinal obstruction and refuses surgical procedure.

## Case Report

An 86-year-old male was admitted to the emergency department with a seven-day history of constipation treated with sennosides and polyethylene glycol without clinical response, his symptomatology worsened by adding abdominal pain, fever, nausea and vomiting.

His personal history included left and right hip replacements 1 and 3 years ago, respectively; chronic constipation, sleep maintenance insomnia and severe mixed dementia (Alzheimer's and vascular) diagnosed 3 years ago; a radical prostatectomy 8 years ago; and being a heavy smoker since a young age (a 40 pack-year history). He was under treatment with citalopram, quetiapine and melatonin due to neuropsychiatric symptoms.

At comprehensive geriatric assessment, severe dependency (Barthel index 0/100), immobility, living with very severe frailty according to the clinical frailty scale, SARC-F of 10 points compatible with probable sarcopenia, malnutrition by mini nutritional assessment of 5 points, and a mini-mental state examination of 19 points indicated impairment in space-time orientation, attention, memory and concentration.

His physical examination revealed a distended abdomen, increased metallic bowel sounds flank and left iliac fossa pain on palpation. A digital rectal examination showed neither stool nor bleeding. Lab tests revealed leukocytosis and neutrophilia. After that, an abdominal X-ray was performed, finding data compatible with intestinal occlusion in the descending colon and sigmoid colon with dilation of 10 cm (Figure 1A). An abdominal computed tomography scan was then performed to rule out the possibility of abdominal pain being caused by

**Address for Correspondence:** Luis E. Martínez-Bravo, Department of Geriatrics, Instituto Mexicano del Seguro Social, Hospital General de Zona, Guadalupe, Mexico

**Phone:** +52 81 800 623 2323 **E-mail:** luisenrique.martinez@udem.edu **ORCID:** orcid.org/0000-0002-5282-7443

**Received:** 22.09.2022 **Accepted:** 30.03.2023

**Cite this article as:** Martínez-Bravo LE, Garza-Rivera JD, Benitez-Mexia JR, Davila-Valero JC. Use of Milk and Molasses Enema in Colonic Obstruction in An Octogenarian. Eur J Geriatr Gerontol 2023;5(2):165-167

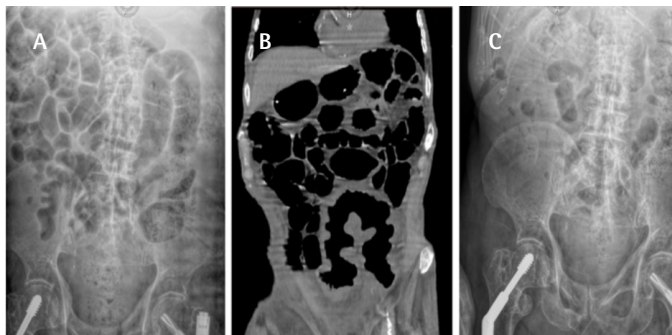


diverticular diseases, volvulus, abscess, or neoplasm, which revealed an intestinal occlusion in the sigmoid colon (Figure 1B).

Conservative management was initiated by placing a nasogastric tube without material drainage; after that, surgical treatment was offered, which the patient and relatives refused for fear of possible surgical complications. Levofloxacin 750 mg was started, as well as "Mayo enemas" every 24 hours for three days, which consisted of "300 milliliters of milk and 50 milliliters of molasses", heated to 35 °C/ 95°F. His labs were as follows prior to the application of enemas: White blood cells  $14 \times 10^9/\mu\text{L}$ , neutrophils  $12 \times 10^9/\mu\text{L}$ , hemoglobin 10 g/dL, platelets  $322 \times 10^9/\mu\text{L}$ , prothrombin time 20.5, INR 1, sodium 131.2 mEq/L, potassium 3.47 mEq/L, chloride 98 mEq/L, phosphorus 2.7 mg/dL, bicarbonate 24 mEq/L, magnesium 2 mg/dL, calcium 8.1 mg/dL, basic urea nitrogen 17.71 mg/dL and creatinine 0.39 mg/dL, where, following application, there was abundant evacuation and symptom relief but no bleeding; intravenous fluids and potassium phosphate replacement were indicated. After 24 hours, his labs did not reveal any electrolyte abnormality, and after three days of enemas and evacuation, an abdominal X-ray was performed, which showed improvement of the occlusion (Figure 1C). His labs were white blood cells  $8.8 \times 10^9/\mu\text{L}$ , neutrophils  $4.9 \times 10^9/\mu\text{L}$ , hemoglobin 10.7 g/dL, platelets  $319 \times 10^9/\mu\text{L}$ , prothrombin time 20.2, INR 1.1, sodium 133 mEq/L, potassium 4 mEq/L, chloride 96.4 mEq/L, phosphorus 3 mg/dL, bicarbonate 22 mEq/L, magnesium 2.2 mg/dL, calcium 8.4 mg/dL, basic urea nitrogen 8.13 mg/dL and creatinine 0.3 mg/dL. After that, polyethylene glycol was added to his prescription, and he was discharged to go home.

## Discussion

The management of geriatric patients is complex. In this case, due to the state of functionality, comorbidities, and family consensus, non-surgical management was decided, so the use of enemas was offered as a conservative therapeutic alternative (5).



**Figure 1.** **A)** Abdominal X-ray revealed intestinal occlusion in the descending colon and sigmoid colon with 10 cm dilation. **B)** Abdominal computed tomography scan, which exhibited an intestinal occlusion in the sigmoid colon. **C)** Abdominal X-ray after "Mayo enemas" with remarkable improvement

The use of enemas based on milk and molasses for constipation has been used in medical practice, although most of the evidence is in the pediatric population. It is postulated that at the gastrointestinal level it produces a hyperosmotic effect and increased gas, promoting softening and expulsion of feces (6,7). However, there are disadvantages and complications as it is an invasive procedure, such as pain, bleeding and intestinal perforation, with an estimated mortality of 38.3% when it happens (8).

Regarding the frequency of complications, studies have produced conflicting results; hemodynamic deterioration and one death have been reported in children after milk enema (9), furthermore, a study reported that in eleven older patients after flee sodium phosphate enema, there was a decline in renal function and five patients died (10). Nevertheless, based on a study in which enemas based on milk and molasses were performed on 159 hospitalized patients, none of these adverse events were reported (11) and in one study of 261 patients in the emergency department, only 3.1% reported complications (8). Additionally, by comparison with sodium phosphate enema, both are described as equally safe and effective (12).

Frailty plays a major role in our medical practice. In the ELF study, frailty increased mortality complications and hospital stay regardless of age in emergency laparotomy, where 50% of patients presented with intestinal obstruction and mortality was 19.5% at ninety days (13); additionally, one study found that after an emergency bowel obstruction operation, 29.8% of patients died within thirty days, and 47.1% had a postoperative complication; this population was older than the ELF population (4).

Overall, intestinal obstruction is an important cause of mortality in older adults, so early identification improves survival. Geriatricians should recognize this disease in older adults, most of the patients respond to medical treatment, but there is a portion who will require a surgical procedure or decompressive endoscopy, which are safe in this population (14). Despite being candidates, some patients and families may object to invasive procedures like those in our case. In this scenario, comorbidities, quality of life, the clinical picture, geriatric syndromes and family expectations are important to making the best decision.

We acknowledge the limitations of using milk and molasses enema for colonic obstruction in older adults, as the majority of the evidence comes from the pediatric population, as well as the possibility of complications following its use. Therefore, we advocate using it as an alternative treatment in specific situations, such as ours, and obtaining written informed consent from family and patients after explaining all of the possible alternatives, all of the above, considering clinical, judgment and individualizing each case. In cases of lactose intolerance, we recommend avoiding it.

This case demonstrates that Mayo enema may be an option in geriatric patients who are unable to undergo surgery or decompressive endoscopy for intestinal obstruction due to medical, environmental, or personal reasons.

The patient's comorbidities prevented the surgeon from performing the surgery, so the enemas were a rapid and efficient option in a grim situation where the patient's life was in danger. The caretakers appreciated the conservative management.

## Ethics

**Informed Consent:** Informed consent was obtained from the patient.

**Peer-review:** Externally peer-reviewed.

## Authorship Contributions

Concept: L.E.M.B., J.C.D.V., Design: L.E.M.B., J.D.G.R., Data Collection or Processing: L.E.M.B., J.D.G.R., Analysis or Interpretation: L.E.M.B., Literature Search: L.E.M.B., J.D.G.R., J.R.B.M., Writing: L.E.M.B., J.D.G.R., J.R.B.M., J.C.D.V.

**Conflict of Interest:** No conflict of interest was declared by the authors.

**Financial Disclosure:** The authors declared that this study received no financial support.

## References

- Perrone G, Giuffrida M, Papagni V, Pattonieri V, Tarasconiv A, Catena F. Management of Acute Large Bowel Obstruction in Elderly Patients. In: Latifi R., Catena F, Coccolini F. (Eds). *Emergency General Surgery in Geriatrics. Hot Topics in Acute Care Surgery and Trauma*. 1st edition. Springer Cham, Springer Nature Switzerland AG, 2021, pp 349-360.
- Catena F, De Simone B, Coccolini F, Di Saverio S, Sartelli M, Ansaloni L. Bowel obstruction: a narrative review for all physicians. *World J Emerg Surg* 2019;14:20.
- Naveed M, Jamil LH, Fujii-Lau LL, Al-Haddad M, Buxbaum JL, Fishman DS, Jue TL, Law JK, Lee JK, Qumsey B, Sawhney MS, Thosani N, Storm AC, Calderwood AH, Khashab MA, Wani SB. American Society for Gastrointestinal Endoscopy guideline on the role of endoscopy in the management of acute colonic pseudo-obstruction and colonic volvulus. *Gastrointest Endosc* 2020;91:228-235.
- Speicher PJ, Lagoo-Deenadayalan SA, Galanos AN, Pappas TN, Scarborough JE. Expectations and outcomes in geriatric patients with do-not-resuscitate orders undergoing emergency surgical management of bowel obstruction. *JAMA Surg* 2013;148:23-28.
- Di Saverio S, Tugnoli G, Orlandi PE, Casali M, Catena F, Biscardi A, Pillay O, Baldoni F. A 73-year-old man with long-term immobility presenting with abdominal pain. *PLoS Med* 2009;6:e1000092.
- Wallaker K, Fortuna E, Bradin S, Macy M, Hassan M, Stanley R. Milk and molasses enemas: clearing things up. *J Emerg Nurs* 2014;40:546-551.
- Vilke GM, DeMers G, Patel N, Castillo EM. Safety and efficacy of milk and molasses enemas in the emergency department. *J Emerg Med* 2015;48:667-670.
- Cirocchi R, Randolph J, Panata L, Verdelli AM, Mascagni D, Mingoli A, Zago M, Chiarugi M, Lancia M, Fedeli P, Davies J, Occhionorelli S. The tip of the iceberg of colorectal perforation from enema: a systematic review and meta-analysis. *Tech Coloproctol* 2020;24:1109-1119.
- Walker M, Warner BW, Brill R, Jacobs BR. Cardiopulmonary compromise associated with milk and molasses enema use in children. *J Pediatr Gastroenterol Nutr* 2003;36:144-148.
- Ori Y, Rozen-Zvi B, Chagnac A, Herman M, Zingerman B, Atar E, Gafter U, Korzets A. Fatalities and severe metabolic disorders associated with the use of sodium phosphate enemas: a single center's experience. *Arch Intern Med* 2012;172:263-265.
- Wangui-Verry J, Farrington M, Matthews G, Tucker SJ. CE: Original Research: Are Milk and Molasses Enemas Safe for Hospitalized Adults? A Retrospective Electronic Health Record Review. *Am J Nurs* 2019;119:24-28.
- Hansen SE, Whitehill JL, Goto CS, Quintero CA, Darling BE, Davis J. Safety and efficacy of milk and molasses enemas compared with sodium phosphate enemas for the treatment of constipation in a pediatric emergency department. *Pediatr Emerg Care* 2011;27:1118-1120.
- Parmar KL, Law J, Carter B, Hewitt J, Boyle JM, Casey P, Maitra I, Farrell IS, Pearce L, Moug SJ; ELF Study Group. Frailty in Older Patients Undergoing Emergency Laparotomy: Results From the UK Observational Emergency Laparotomy and Frailty (ELF) Study. *Ann Surg* 2021;273:709-718.
- Belle S. Endoscopic Decompression in Colonic Distension. *Visc Med* 2021;37:142-148.